



(11)

EP 3 174 540 B9

(12) **CORRECTED EUROPEAN PATENT SPECIFICATION**

(15) Correction information:
Corrected version no 1 (W1 B1)
Corrections, see
Description Paragraph(s) 7

(48) Corrigendum issued on:
05.05.2021 Bulletin 2021/18

(45) Date of publication and mention
of the grant of the patent:
02.09.2020 Bulletin 2020/36

(21) Application number: **15827946.3**

(22) Date of filing: **30.07.2015**

(51) Int Cl.:
A61K 31/519 ^(2006.01) **A61K 9/00** ^(2006.01)
A61P 27/02 ^(2006.01) **A61K 9/50** ^(2006.01)

(86) International application number:
PCT/US2015/042951

(87) International publication number:
WO 2016/019165 (04.02.2016 Gazette 2016/05)

(54) **METHOTREXATE FOR PROLIFERATIVE VITREORETINOPATHY**
METHOTREXAT ZUR PROLIFERATIVEN VITREORETINOPATHIE
MÉTHOTREXATE POUR LE TRAITEMENT DE LA VITRÉORÉTINOPATHIE PROLIFÉRANTE

(84) Designated Contracting States:
AL AT BE BG CH CY CZ DE DK EE ES FI FR GB
GR HR HU IE IS IT LI LT LU LV MC MK MT NL NO
PL PT RO RS SE SI SK SM TR

(30) Priority: **30.07.2014 US 201462030778 P**

(43) Date of publication of application:
07.06.2017 Bulletin 2017/23

(60) Divisional application:
20191599.8 / 3 791 883

(73) Proprietor: **Massachusetts Eye & Ear Infirmary**
Boston, MA 02114 (US)

(72) Inventors:
• **ELIOTT, Dean**
Carlsbad, California 92009 (US)
• **STRYJEWSKI, Tomasz P.**
Boston, Massachusetts 02114 (US)

(74) Representative: **Forresters IP LLP**
Skygarden
Erika-Mann-Straße 11
80636 München (DE)

(56) References cited:
WO-A1-2014/074823 US-A1- 2004 253 243
US-A1- 2005 255 144 US-A1- 2006 073 182
US-A1- 2008 241 221 US-A1- 2009 081 277
US-A1- 2011 200 662 US-A1- 2014 105 956

- **HARDWIG PAUL W ET AL: "The safety of intraocular methotrexate in silicone-filled eyes", RETINA, vol. 28, no. 8, September 2008 (2008-09), pages 1082-1086, XP009501801, ISSN: 0275-004X**
- **HARDWIG P W ET AL: "Intraocular Methotrexate in Ocular Diseases Other Than Primary Central Nervous System Lymphoma", AMERICAN JOURNAL OF OPHTHALMOLOGY, ELSEVIER, AMSTERDAM, NL, vol. 142, no. 5, 1 November 2006 (2006-11-01), pages 883-885, XP027911086, ISSN: 0002-9394 [retrieved on 2006-11-01]**
- **OWEN ET AL.: 'Preliminary Results Of Treatment With Intravitreal Methotrexate In Patients With Macula Oedema Secondary To Uveitis' ASSOCIATION FOR RESEARCH IN VISION AND OPHTHALMOLOGY ANNUAL MEETING 2012, XP055394806**

Note: Within nine months of the publication of the mention of the grant of the European patent in the European Patent Bulletin, any person may give notice to the European Patent Office of opposition to that patent, in accordance with the Implementing Regulations. Notice of opposition shall not be deemed to have been filed until the opposition fee has been paid. (Art. 99(1) European Patent Convention).

EP 3 174 540 B9

- **YEH ET AL.:** 'Combination intravitreal rituximab and methotrexate for massive subretinal lymphoma' EYE vol. 24, 01 January 2010, pages 1625 - 1627, XP055392131 DOI: 10.1038/EYE.2010.91
- **SUNALP M ET AL:** "Effects of cytotoxic drugs on proliferative vitreoretinopathy in the rabbit cell injection model", CURRENT EYE RESEARCH, INFORMA HEALTHCARE USA, US, vol. 3, no. 4, 31 March 1984 (1984-03-31), pages 619-623, XP009501814, ISSN: 0271-3683, DOI: 10.3109/02713688409003063

Description**CLAIM OF PRIORITY**

5 **[0001]** This application claims the benefit of U.S. Patent Application Serial No. 62/030,778, filed on July 30, 2014.

TECHNICAL FIELD

10 **[0002]** This invention relates to the use of methotrexate, e.g., repeated dosing of methotrexate, for reducing risk of proliferative vitreoretinopathy (PVR) or epiretinal membranes (ERM) after surgical vitrectomy and/or scleral buckle to treat retinal detachment.

BACKGROUND

15 **[0003]** Retinal detachment (RD) is an important cause of sudden visual loss in the United States, with approximately 40,000 cases occurring annually. Permanent visual loss will result if treatment is delayed.

20 **[0004]** A retinal detachment is defined as the separation of the neurosensory retina from the retinal pigment epithelium (RPE). In the nonpathologic state, the retinal pigment epithelium is a continuous epithelial monolayer occluded by tight junctions, which maintain a strict separation of the underlying choroidal capillary beds from the photoreceptors of the sensory retina, thus forming the outer blood-retina barrier. Its functions include the nourishment of photoreceptors, elimination of waste products, and reabsorption of subretinal fluid.

25 **[0005]** The definitive treatment of retinal detachment is surgical repair. Multiple operative techniques are available to the treating retinologist, but the principles underlying treatment of retinal detachment remain the same: removal of fluid from the subretinal space, relief of any existing traction, and treatment and prophylaxis against the underlying cause for the ingress of fluid, whether it be due to a retinal break or an exudative process.

30 **[0006]** Proliferative vitreoretinopathy (PVR) is the most common cause for failure of retinal detachment surgery, a complication which occurs in 5-10% of all retinal detachment surgeries. PVR can also occur spontaneously in the absence of surgery. PVR is most likely to develop following repeated surgical instrumentation of the eye, following significant physiologic insult to the eye such as in trauma, as well as in retinal detachments complicated by multiple tears, giant tears, vitreous hemorrhage, or in eyes with uveitis.

35 **[0007]** A milder form of PVR, called macular pucker or epiretinal membrane (ERM), complicates the post-operative course of 20-30% of RD surgeries and half of these are so visually distorting that patients will require surgery. In addition, autopsy studies show that close to 75-80% of patients with RD surgery have histological evidence of proliferative membranes. This may explain why many patients do not achieve perfect vision postoperatively after RD surgery, yet do not have any clinically obvious ERMs. In addition, ERMs can also develop spontaneously. SUNALP M ET AL: "Effects of cytotoxic drugs on proliferative vitreoretinopathy in the rabbit cell injection model", CURRENT EYE RESEARCH, vol. 3, no. 4, 31 March 1984, pages 619-623, discloses the effects of a single injection adriamycin, 5-fluorouracil, triamcinolone or methotrexate in an *in-vivo* model of PVR.

40 **[0008]** No treatments to date have been found to be preventive against PVR or ERMs. Once PVR or ERMs develop, surgery is the only treatment.

SUMMARY

45 **[0009]** The invention is defined by the claims. Any subject-matter falling outside the scope of the claims is provided for information purposes only. Furthermore, any references in the description to methods of treatment refer to the compounds, pharmaceutical compositions and medicaments of the present invention for use in a method of treatment of the human or animal body by therapy.

50 **[0010]** In particular, the present invention is directed to a composition for use in treating or reducing the risk of proliferative vitreoretinopathy (PVR) or epiretinal membranes (ERM) in a subject, wherein the composition comprises methotrexate and the methotrexate is administered via a plurality of intravitreal injections over a period of at least one, two, three, or more months, given no more frequently than weekly.

55 **[0011]** The present invention is based, at least in part, on the development of methods to treat and to reduce the risk of developing PVR or ERM.

60 **[0012]** Thus, in a first aspect the invention provides methods for treating or reducing the risk of proliferative vitreoretinopathy (PVR) or epiretinal membranes (ERM) in a subject. The methods include administering a plurality, e.g., ten or more, intravitreal injections of methotrexate over a period of at least one, two, three, or more months, given no more frequently than weekly.

65 **[0013]** In some embodiments, each injection provides a dose of 400 mcg in 0.1 ml methotrexate.

[0014] In some embodiments, the methotrexate is administered posterior to the limbus.

[0015] In some embodiments, the subject is undergoing an ocular surgical procedure that increases the subject's risk of developing ERM or PVR, e.g., a pars plana vitrectomy (PPV), Retinal Detachment (RD) surgery; ERM surgery; scleral buckle surgery; or a procedure in the other eye. In some embodiments, the subject requires a PPV to treat a rhegmatogenous retinal detachment secondary to trauma; preexisting proliferative vitreoretinopathy (e.g., grade C or higher); or for other indications associated with high risk condition for PVR development, e.g., giant retinal tears (giant retinal tears are defined as tears involving 90° or more of the circumference of the globe), retinal breaks larger than 3 disc areas, long-standing retinal detachments, or detachments associated with hemorrhage.

[0016] In some embodiments, a first injection is given at conclusion of the surgical procedure; eight weekly injections are given until postoperative month two; and a final tenth injection is given at postoperative month three.

[0017] In some embodiments, the methods include administering nine consecutive weekly injections, and a tenth injection three months after the first injection.

[0018] In some embodiments, the methods include administering additional injections monthly after the final, e.g., tenth, injection.

[0019] In some embodiments, the methods include administering one, two, three, four, five, six, seven, eight, or nine additional injections, e.g., monthly, after the tenth injection.

[0020] In another aspect, the present disclosure provides methods for treating or reducing the risk of PVR or ERM in a subject. The methods include intravitreally administering a sustained release formulation of methotrexate over at least a three-month period.

[0021] In some aspects, the sustained release formulation is or comprises a lipid-encapsulated formulation; multivesicular liposome (MVL) formulations of methotrexate (MTX); nano- or microparticles; polyion complex (PIC) micelles; or bioadhesive polymers. In some embodiments, the bioadhesive polymers comprise one or more of hydroxypropyl methylcellulose (HPMC), carboxymethylcellulose (CMC), polyacrylic acid (PAA), or hyaluronic acid (HA).

[0022] In a further aspect, the disclosure provides methods for treating or reducing the risk of PVR or ERM in a subject. The methods include implanting a device for sustained release of methotrexate over at least a three-month period into the eye of the subject.

[0023] In some embodiments, the device is non-biodegradable.

[0024] In general, in the methods described herein, the subject does not have cancer, e.g., does not have an ocular cancer, e.g., does not have ocular or B cell lymphoma. In some embodiments, the subject does not have uveitis. In some embodiments, the methods include determining that a subject has or is at risk of developing PVR or ERM, or is about to undergo a procedure with a high risk of PVR or ERM as a side effect, and selecting the subject.

[0025] Unless otherwise defined, all technical and scientific terms used herein have the same meaning as commonly understood by one of ordinary skill in the art to which this invention belongs. Methods and materials are described herein for use in the present invention; other, suitable methods and materials known in the art can also be used. The materials, methods, and examples are illustrative only and not intended to be limiting.

[0026] Other features and advantages of the invention will be apparent from the following detailed description and figures, and from the claims.

DESCRIPTION OF DRAWINGS

[0027]

FIG. 1 is a flowchart showing an exemplary treatment protocol using the present methods.

FIGs. 2A-2C are each sets of nine images of human PVR cells plated into 12 wells with 30,000 cells per well showing that methotrexate inhibited proliferation of human proliferative vitreoretinopathy (PVR) cells in culture. The cells were treated with 100 μ M, 200 μ M, or 400 μ M Methotrexate (MTX) as indicated, and the images were taken after 72 hours (2A), 1 week (2B) or 2 weeks (2C). At 72 hours (2A), the photomicrograph showed similar epithelioid morphology and limited confluence across the control plates (top row), as well as the three methotrexate concentrations (rows 2-4). At 1 week (2B), the control plates (row 1) showed a uniform, confluent cellular sheet whereas rows 2-4, which were exposed to methotrexate 400, 200, and 100 respectively, showed growth inhibition and lack of confluency, and were less epithelioid in appearance. At 2 weeks, the control plates (row 1) continued to be a uniform, confluent cellular sheet, whereas rows 2-4, exposed to methotrexate 400, 200, and 100 respectively, continued to have inhibited growth and lack of confluency.

DETAILED DESCRIPTION

[0028] Proliferative vitreoretinopathy (PVR) is a common occurrence after retinal detachment surgery. PVR is a "scarring" condition that forms inside the eye after surgery, significant trauma, or even spontaneously. Its pathogenesis is

the disruption of the retinal pigment epithelium layer, which is associated with inflammation, migration, and proliferation of cells to the (neural) retinal surface. Over the next 4-12 weeks, membranes on the surface of the retina proliferate, contract, and apply traction on the retina, which results in redetachment of the retina from the RPE. Once PVR is present and the retina detaches for a second time, it is unlikely that vision will be restored.

Pathobiology of Proliferative Vitreoretinopathy (PVR) and Epiretinal Membranes (ERM)

[0029] Epiretinal membranes (ERM) are caused by an abnormal proliferation of cells, e.g., retinal pigment epithelial (RPE) cells, glial cells, fibroblasts, and macrophages, on the surface of the retina, typically in response to ocular disease; the membranes tend to contract and cause puckering and thus distortion of the macula. See, e.g., Hiscott et al., *Br J Ophthalmol.* 68(10):708-15 (1984); Hiscott et al., *Eye* 16, 393-403 (2002); and Asato et al., *PLoS One.* 8(1): e54191 (2013).

[0030] Like ERM, PVR is an abnormal wound healing response of the vitreous and retina, a clinical syndrome where cells with proliferative capacity, driven by inflammatory mediators, multiply on the retinal surface, contract, and eventually cause recurrent retinal detachment (RD). The pathogenesis of PVR begins with the introduction of RPE cells into the vitreous cavity. These cells may be introduced at the time of the retinal tear itself or may be introduced iatrogenically such as through the use of cryotherapy or retinectomy. Studies from monkey eyes with PVR have also postulated that the introduction of Müller cells, as well as potentially fibrocytes, occur as well. Concomitant with the introduction of RPE cells is the introduction or upregulation of growth factors, including vascular endothelial growth factor (VEGF), platelet-derived growth factor (PDGF), fibronectin, transforming growth factor-beta (TGF- β), and other mediators. This process begins an autocrine loop where glial, RPE, and other cellular constituents proliferate and transdifferentiate into contractile myofibrocytes. On pathology, macrophages as well as fibroblasts are commonly identified in specimens of PVR.

[0031] It has also been proposed that, at this time of RPE disruption, inflammation plays an important role in the development of PVR. Cytokines IL-6, IL-1, TNF-alpha, and IFN-gamma have been identified in high concentrations in the vitreous in the early, proliferative stages of PVR, but they decrease to normal levels in the scarring phase. These cytokines are not present in eyes that do not develop PVR.

[0032] The use of a pharmacologic adjuvant to prevent PVR has been an elusive goal in ophthalmology. A general pharmacologic strategy employed in prior PVR studies has been the single intravitreal, intraoperative administration of a variety of agents, such as duanoribicin, 5-fluorouracil (5-FU), triamcinolone, low-molecular weight heparin, and naproxen.¹⁰⁻¹⁵ Although the clearance of vitreally delivered drugs is dependent on a number of factors including the molecular weight of the drug, the status of the blood-retina barriers, contents of the vitreous cavity, etc., it is likely that those drugs used in these prior PVR studies were cleared from the eye within days after their administration. In contrast, PVR does not become a clinically appreciable, pathologic entity until at least 6-8 weeks after surgery.

Methotrexate

[0033] Methotrexate is a non-naturally occurring chemically also known as N-[4-[(2,4-diamino-6-pteridiny) methyl] methylamino] benzoyl]-L-glutamic acid. A folate analog, methotrexate is thought to act as an anti-proliferative agent by reversibly inhibiting dihydrofolate reductase, which prevents dihydrofolate from being reduced to tetrahydrofolate, which is used in the synthesis of purine nucleotides.

[0034] Mechanisms of anti-inflammatory action are less clear, although mechanisms that have been proposed include its ability to enhance the extracellular concentration of adenosine, suppression of pro-inflammatory cytokines, inducement of apoptosis of activated T cells, and suppression of intracellular adhesion by activated T cells.

[0035] In some embodiments, the methotrexate is formulated for repeated injection, e.g., in Balanced Salt Solution from 25 mg vials to a sterile, single-use dose of 400 mcg/0.1 ml.

[0036] In some aspects, the methotrexate is formulated for sustained release. A number of sustained release formulations of methotrexate are known in the art, including but not limited to biodegradable implants such as lipid-encapsulated formulations, e.g., Depo/Methotrexate, as described in Bonetti et al., *Cancer Chemother Pharmacol* 33:303-306 (1994) and Chatelut et al., *J Pharm Sci.* 1994 Mar;83(3):429-32; multivesicular liposome (MVL) formulations of methotrexate (MTX), e.g., as described in WO2011143484; nano- or microparticules, e.g., alpha-lactalbumin microparticles, e.g., as described in Vijayaragavan et al., *Int J Pharm Res* 3(1):39-44 (2011) or nanoparticles of conjugated methotrexate-human serum albumin as described in Taheri et al., *J Nanomaterials* 2011 (dx.doi.org/10.1155/2011/768201); polyion complex (PIC) micelles; bioadhesive polymers such as hydroxypropyl methylcellulose (HPMC), carboxymethylcellulose (CMC) and polyacrylic acid (PAA) derivatives, as well as hyaluronic acid (HA), e.g., Lacrisert (Aton Pharma), which is a soluble hydroxy propyl cellulose ocular insert.

[0037] Alternatively or in addition, sustained release can be achieved using a sustained-release device such as intravitreal implants, e.g., as described in Palakurthi et al., *Current Eye Research*, 35(12):1105-1115 (2010) or similar to the Retisert (Bausch & Lomb), Ozurdex (Allergan); or non-biodegradable implants, e.g., similar to Iluvien (Alimera) or Vitrasert

(Bausch & Lomb) implants; the I-vation platform (SurModics Inc.). See also Lee et al., Pharm Res. 27(10):2043-53 (2010); Haghjou et al., J Ophthalmic Vis Res. 6(4):317-329 (2011); Kim et al., Invest. Ophthalmol. Vis. Sci. 45(8):2722-2731 (2004); and Velez and Whitcup, Br J Ophthalmol 83:1225-1229 (1999).

Subjects

[0038] The methods described herein can be used to prevent (reduce the risk of) PVR or ERM in patients, e.g., in patients requiring pars plana vitrectomy (PPV), e.g., for rhegmatogenous retinal detachment secondary to trauma; for patients requiring PPV for preexisting proliferative vitreoretinopathy grade C or higher; and/or for patients with retinal detachments requiring PPV for other indications associated with high risk condition for PVR development, e.g., giant retinal tears (giant retinal tears are defined as tears involving 90° or more of the circumference of the globe), retinal breaks larger than 3 disc areas, long-standing retinal detachments, or detachments associated with hemorrhage.

[0039] Other uses of sustained methotrexate in the eye in addition to PVR include the following:

Prevention of Epiretinal Membranes after Retinal Detachment (RD) surgery

[0040] Approximately 20-30% of RD cases develop clinically perceptible ERMs. Half of these are so visually distorting that patients will require surgery. In addition, autopsy studies show that close to 75-80% of patients with RD surgery have some degree of proliferative of membranes. This may explain why many patients do not achieve perfect vision postoperatively after RD surgery, yet do not have any ERMs grossly perceptible to the human eye.

Prevention of ERMs that develop spontaneously

[0041] ERMs can develop spontaneously, which then requires surgery. If a subject developed an ERM in one eye, implanting a device to prevent ERMs in the other eye could prevent development in that eye.

Prevention of secondary ERM after ERM surgery

[0042] For patients who develop ERMs, these can be removed but some reoccur and require reoperation. Leaving an implant could prevent the recurrent ERM.

[0043] The methods described herein can include identifying and/or selecting a subject who is in need of treatment to prevent the development of PVR or ERM as a result of a condition listed above (e.g., selecting the subject on the basis of the need of treatment as a result of a condition listed above, e.g., an increased risk of developing PVR or ERM as a result of a condition listed above). In some embodiments, the subjects treated with a method described herein do not have ocular cancers, e.g., do not have lymphoma (e.g., B cell lymphoma), and/or do not have uveitis.

[0044] The presentation of PVR clinically encompasses a wide phenotype. PVR can vary from a mild cellular haze (Grade A) to thick, fibrous membranes that cause the characteristic stiffened funnel of the detached retina (Grade D). A number of grading systems are in use, see, e.g., Ryan, Retina, 5th ed (Elsevier 2013); Retina Society Terminology Committee. The classification of retinal detachment with proliferative vitreoretinopathy. Ophthalmology 1983;90:121-5 (1983); Machemer R, Aaberg TM, Freeman HM, et al. Am J Ophthalmol 112:159-65 (1991); Lean J, Irvine A, Stern W, et al. Classification of proliferative vitreoretinopathy used in the silicone study. The Silicone study group. Ophthalmology 1989;96:765 - 771. In some embodiments the methods include identifying, selecting, and/or treating a subject who has a low grade (e.g., Grade A or Grade 1) PVR, or who has ERM. In some embodiments, the methods include monitoring the subject for early signs of the development of PVR or ERM, i.e., the presence of a "vitreous haze" indicating a cellular proliferation (which may eventually develop into an organized sheet), and administering one or more doses of MTX as described herein. Although early Grade A PVR vs. an early ERM may be difficult to distinguish from one another, eventually untreated PVR will progress; ERMs will cause a mild traction on the macula resulting in metamorphopsia but will not cause detachment of the retina, whereas untreated PVR will cause detachment and eventually result in a funneled, atrophic retina. The methods can also be used to treat subjects without present signs of PVR but who are at risk for PVR or ERMs.

Methods of Treating or Reducing Risk of PVR or ERM

[0045] The methods described herein include the use of methotrexate in subjects who are at risk of developing a first or recurring PVR or ERM, e.g., a subject who is undergoing RD surgery or ERM surgery, as described above, and in subjects who have PVR or ERM or who are at risk for developing PVR or ERMs. In some embodiments, the methods described herein include the use of methotrexate in subjects who have undergone, are undergoing, or will undergo a pars plana vitrectomy (PPV) or scleral buckle (SB). In some embodiments, the methods include performing a PPV, RD

surgery, or ERM surgery. Methods for performing these surgeries are known in the art; for example, typically, PPV is performed under local or general anesthesia using three, 23 or 20 gauge sclerotomy ports. Any present epiretinal membranes can be dissected, e.g., using a membrane pick and forceps. Intraoperative tissue staining, perfluorocarbons, cryopexy, endolaser, scleral buckling, and lensectomy can also be performed as needed. Standard tamponading agents can be used, e.g., silicone oil or gas.

[0046] The methods described herein include the use of an effective amount of methotrexate. An "effective amount" is an amount sufficient to effect beneficial or desired results, e.g., the desired therapeutic effect (i.e., a prophylactically effective amount that reduces the risk of developing PVR or ERM). An effective amount can be administered in one or more administrations, applications or dosages. A therapeutically effective amount of methotrexate can be, e.g., 400 µg/0.1 ml per injection, e.g., with at least ten injections, giving a cumulative dose of 4,000 µg over ten injections; in some embodiments, the methods include giving more than ten injections, for a cumulative dose of more than 4,000 µg. In some embodiments, the methods include giving fewer than ten injections, for a cumulative dose of less than 4,000 µg. The compositions can be administered one or more times per month. The skilled artisan will appreciate that certain factors may influence the dosage and timing required to effectively treat a subject, including but not limited to the severity of the disease or disorder, previous treatments, the general health and/or age of the subject, and other diseases present.

[0047] In some embodiments, intravitreal methotrexate injections are performed aseptically after the topical application of anaesthesia and an antiseptic agent, e.g., 5% povidone iodine, to the conjunctival sac. In some embodiments, each subject receives an intravitreal injection of methotrexate, e.g., 400 mcg/0.1 ml methotrexate, 3.0 to 3.5 mm posterior to the limbus, depending on lens status, with a 30-gauge needle.

[0048] In some embodiments, the subjects receive multiple intravitreal injections of methotrexate during their post-operative period. The first injection can be administered intraoperatively; subsequently, injections can be administered on post-operative (post-op) weeks 1, 2, 3, 4, 5, 6, 7, and 8, and on post-op month 3, for a total of 10 injections. See, e.g., Figure 1. In some embodiments, the methods include administering the methotrexate in ten doses, or ten or more doses, or less than ten doses, over a three-month period or longer, and injections would be given no more frequently than weekly. In some embodiments, the methods include additional doses at weekly, biweekly, or monthly frequency thereafter for an additional one, two, three, four, five, six, seven, eight, nine, ten, 11, or 12 months thereafter. In some embodiments the methods include ten doses over three months as shown in Fig. 1, with an optional additional one or more doses at monthly intervals thereafter for an additional one, three, six, or more months thereafter.

[0049] In some aspects, the subjects receive a sustained release implant, e.g., as described above, that will release MTX over time, e.g., over a week, two weeks, a month, two months, three months, six months, or a year. In some aspects, the methods include administering subsequent implants to provide MTX administration for at least six months, one year, two years, or more.

EXAMPLES

[0050] The invention is further described in the following examples, which do not limit the scope of the invention described in the claims.

Example 1. Sustained methotrexate in the silicone filled postoperative eye at high risk for proliferative vitreoretinopathy

[0051] We hypothesized that the administration of multiple, intravitreal methotrexate injections into eyes with high-risk features for post-operative proliferative vitreoretinopathy (PVR) development will have improved visual outcomes, higher anatomic final reattachment rates, decreased reoperation rates, and decreased occurrence of PVR at 4 months post-operatively.

[0052] We have performed a small pilot study in 10 patients with retinal detachment whom had high-risk clinical factors for developing PVR.

[0053] Patients 18 years to 89 years old of both genders were eligible for this study if they required pars plana vitrectomy (PPV) for rhegmatogenous retinal detachment secondary to trauma, PPV for preexisting proliferative vitreoretinopathy grade C or higher, or if they had retinal detachments requiring PPV for other indications associated with high risk condition for PVR development, i.e.: giant retinal tears (Giant retinal tears are defined as tears involving 90° or more of the circumference of the globe), retinal breaks larger than 3 disc areas, long-standing retinal detachments, detachments associated with hemorrhage.

[0054] The PPV was performed under local or general anesthesia using three, 23 or 20 gauge sclerotomy ports. Any present epiretinal membranes were dissected using a membrane pick and/or forceps. Intraoperative tissue staining, perfluorocarbons, cryopexy, endolaser, scleral buckling, and lensectomy were performed as needed. Either silicone oil or gas was used as the tamponading agent.

[0055] Routine post-operative visits, which involve a dilated funduscopy examination, occurred on post-operative day

1, 7, month 1, month 2, and month 3. Patients return to the operating room after three months for silicone oil removal and were seen in clinic 4 months after the original surgery.

[0056] In addition to receiving the above-described standard of care, patients received multiple intravitreal methotrexate injections during their post-operative period. The first injection was administered intraoperatively and subsequently was injected on post-op week 1,2,3,4,5,6,7,8 and on post-op month 3, for a total of 10 injections. Intravitreal methotrexate injections were performed aseptically after the topical application of anaesthesia and 5% povidone iodine to the conjunctival sac. Each patient received an intravitreal injection of 400mcg/0.1ml methotrexate, 3.0 to 3.5 mm posterior to the limbus, depending on lens status, with a 30-gauge needle.

[0057] After injection, patients were monitored for adverse events, including a full-dilated funduscopy examination.

Demographics and pre-operative vision

[0058] Eight men and two women enrolled into the study (Table 1). The age of patients ranged from 18 to 63. Two patients (#4 & #9) were enrolled with traumatic retinal detachment (total retinal detachment, 360 degree giant retinal tear, and retina incarcerated in scleral wound after open globe injury). The remaining 8 patients had had multiple (average 2.5) prior retinal detachments secondary to proliferative membranes. One patient (MTX08M) had significant baseline retinal comorbidity with high pathologic myopia, staphyloma, atrophy, lattice and paving stone in the operative eye. The median pre-operative visual acuity was Hand Motions at 2 feet.

Operative details

[0059] Operative details of each patient are provided in Table 2. Operative time was recorded as a surrogate for surgical complexity. All patients underwent vitrectomy, extensive membrane peeling, relaxing retinectomy, perfluoro-carbon liquid, endolaser, and silicone oil injection. The four subjects previously surgically intervened on had buckles that were still providing adequate indentation of the globe and were therefore left in place.

Visual and anatomical results

[0060] Despite the extremely poor visual and anatomic prognosis of all the subjects enrolled in the study, no subjects developed PVR while receiving methotrexate during the three-month treatment protocol. Interestingly, one of the trauma patients (#4) experienced massive PVR two weeks after completion of the injection protocol (at 3 ½ months postoperatively), but weekly examination during the study had shown no evidence of proliferating cells; this is extremely unusual and may be accounted for by the presence of methotrexate for three months and its subsequent absence. This patient required re-operation. Two other subjects developed reaccumulation of fluid under the retina requiring re-operation, but no membranes were appreciated.

Safety and adverse events

[0061] Adverse events observed are reported in Table 3. All subjects experienced a degree of conjunctival hyperemia, consistent with the use of silicone oil. Superficial punctate keratopathy (SPK) was observed in one asymptomatic patient at a single clinical exam. Examination one week later showed a normal corneal surface and no further sequelae were observed. Follow up duration in our 10 patients ranged from 4 months to 39 months, with a median follow up time of 25 months. Even after months to years of follow up data, no significant adverse events were observed. Visual acuity and intraocular pressure at the last follow up visit was similar in all patients to the visual acuity and pressure observed at post-operative month 4, at the conclusion of the study period, suggesting good long term safety.

[0062] In addition, in the same patient who experienced SPK, elevated intraocular pressure was documented (44 mm Hg by Goldmann Tonometry) at a single examination. Per patient report, she had been taking Flonase (fluticasone nasal) "many times per day" and had been taking Pred Forte drops QID, although she had been instructed to take Pred Forte BID. Her pressure was normalized in the exam room with topical therapy. The intravitreal injection was administered as scheduled, and she was discharged from clinic with normal pressure. She was given a prescription for Alphagan and Xalatan with plans to follow up with the Glaucoma service. No further elevated pressures were observed during the course of the study or in follow up, suggesting that her transient elevated pressure was most likely due to excessive steroid use as suspected. Patient MTX08M ended the study with NLP vision. He had a history in the operative eye of pathological myopia, staphyloma, atrophy, lattice, and pave stoning. One month after his surgery (his third intravitreal surgery in that eye and the study surgery date), disc pallor was noted. Optical coherence tomographic pictures of that retina before and after had noted disorganized laminae, secondary to his underlying retinal disease. His vision at this was noted to be LP. He continued to receive injection with limited improvement in his vision and noted to be NLP at the final visit.

[0063] In addition to the excellent anatomical results seen, with virtually no PVR developing during the study protocol, the protocol was associated with excellent visual results. The median post-operative visual acuity was 20/200. This is notable because although one other group has used methotrexate in eyes with a wide variety of conditions, including PVR, no one has previously demonstrated improved outcomes. Hardwig et al. injected methotrexate intravitreally of varying doses into 5 patients, however, only one patient had any improved vision and there was no change in visual acuity for the group (Hardwig et al., Retina 28:1082-1086 (2008)). In addition, this study did not attempt to validate efficacy. Also, in 2006 Hardwig et al. injected 1 dose of methotrexate into the anterior chamber of one patient with PVR, but not into the intravitreal space as described herein (Hardwig et al., Am J Ophthalmol 2006;142:883-885 (2006)).

[0064] The present results are very encouraging and are unlikely explained by chance. The patients who have received 10 intravitreal methotrexate injections have done remarkably well given the severity of their condition, as we intentionally selected patients who were at the highest risk for PVR.

Example 2. Sustained methotrexate inhibits the growth of proliferative vitreoretinopathy *in vitro*

[0065] We hypothesized that methotrexate would inhibit human proliferative vitreoretinopathy (PVR) cells in culture. PVR membranectomy was performed in patients undergoing retinal detachment repair secondary to PVR. Using cellular separation techniques, cellular constituents of the PVR membranes were separated from the extracellular matrix membranes. 30,000 cells per well were placed into a standard 12 well plate. All 12 wells received endothelial cell growth medium with supplemental growth factors. Four arms were designated consisting of three wells each. The first arm served as a control receiving the standard growth medium but no other intervention. The remaining wells were designated as treatment arms. The second arm of three wells served as the first treatment arm and exposed the cells to 400 micrograms of methotrexate. The third and fourth arms of three wells each exposed the cultured cells to 200 and 100 micrograms, respectively, of methotrexate.

[0066] At 72 hours, similar growth of PVR cells with typical epithelioid morphology and limited confluence was observed (Figure 2a). One week after seeding (Figure 2b) the PVR control cells demonstrated a confluent cellular sheet whereas cells exposed to methotrexate at all concentrations demonstrated growth inhibition, lack of confluency, and were less epithelioid in appearance. At two weeks (Figure 2C), inhibition of cellular confluency continued whereas the control plates continued to proliferate.

Table 1 Patient demographics							
studyid	Age	Male	Race	Criteria for entry	Childbearing potential	Ocular comorbidities	Previous number of surgeries attempted to repair RD
MTX01F	47	No	White	PVR Grade C	No	none	3
MTX02M	60	Yes	White	PVR Grade C	No	none	3
MTX03M	56	Yes	White	PVR Grade C	No	lattice, mild cataract	3
MTX04M	25	Yes	White	RD associated with open globe injury	No	Marginal lid laceration of right lower lid with canilicular involvement	0
MTX05M	29	Yes	White	PVR Grade C	No	subluxated lens OS, lens removal age 4, diagnosed glaucoma age 11, post capsule removal age 17 subluxated lens OD, lens removal age 17	2
MTX06M	54	YES	White	PVR Grade C	No	none	3
MTX07M	57	YES	White	PVR Grade C	No	none	2
MTX08M	63	Yes	White	PVR Grade C	No	High Pathologic myopia; staphyloma OU; atrophy OU; lattice and paving stone OS	2
MTX09M	53	Yes	White	RD associated with open globe injury	No	none	0
MTX10F	18	NO	White	PVR Grade C	Yes, 2 methods of contraception + pregnancy test prior to every injection	s/p 5 prior strabismus surgeries	2

Patients enrolled in year 1

Patients enrolled in year 2

Table 2 Clinical results										
studyid	Visual Acuity, initial	Visual Acuity, Post-op month 4	Initial IOP	Final IOP	Injections	Detachments	Last follow up date	Total months of follow up	Visual acuity at last follow up	IOP at last follow up
MTX01F	HM	20/200	22	13	10	0	7/9/15	39	20/150	12
MTX02M	640	20/320	12	12	10	0	5/20/15	38	20/500	15
MTX03M	HM	20/200	9	12	10	0	7/14/15	39	20/300	16
MTX04M	LP	20/160	10	9	10	0*	7/1/15	37	HM	9
MTX05M	600	20/200	11	10	10	0	12/3/12	4	20/200	9
MTX06M	LP	20/252	soft	8	10	0	7/1/15	27	CF	9
MTX07M	HM	20/200	12	12	10	0	4/8/15	24	CF	22
MTX08M	CF	NLP	14	15	10	0	9/17/14	15	NLP	14
MTX09M	LP	20/65	soft	9	10	0	4/29/15	22	20/70	16
MTX10F	HM	CF	15	13	9	0	3/24/15	16	CF	14
*Massive PVR membranes developed two weeks after the final injection of methotrexate, despite there being no PVR in the preceding three months										
Injections: Total number of injections of methotrexate 400mcg/0.1ml										
Detachments: Number of detachments due to PVR during study period										

Patients
enrolled in year

Patients
enrolled in year

Table 3 Adverse events observed in subjects								
	studyid	Conjunctival hyperemia	Superficial Punctate Keratopathy	Elevated intraocular pressure	NLP	Reoperations required	Date of reoperation	Indication for reoperation
Patients enrolled in year 1	MTX01F	7	1	1	0	0	-	-
	MTX02M	7	0	0	0	0	-	-
	MTX03M	5	0	0	0	0	-	-
	MTX04M	4	0	0	0	1	Post-op month 4	Outside the injection period (post-op month 3.5), significant PVR was seen. Patient was taken to the OR to peel membranes and remove traction from the retina.
	MTX05M	7	0	0	0	1	Post-op month 2.5	Persistent sub-retinal fluid, no membranes
	MTX06M	5	0	0	0	0	-	-
	MTX07M	4	0	0	0	0	-	-
	MTX08M	6	0	0	1	0	-	-
	MTX09M	6	0	0	0	0	-	-
	MTX10F	5	0	0	0	0	-	-
Patients enrolled in year 2								

REFERENCES

[0067]

1. Frenkel S, Hendler K, Siegal T, et al. Intravitreal methotrexate for treating vitreoretinal lymphoma: 10 years of experience. *British Journal of Ophthalmology* 2008;92:383-388.
2. Fishburne BC, Wilson DJ, Rosenbaum JT, Neuwelt EA. Intravitreal methotrexate as an adjunctive treatment of intraocular lymphoma. *Arch Ophthalmol* 1997;115:1152-1156.
3. de Smet MD, Vancs VS, Kohler D, et al. Intravitreal chemotherapy for the treatment of recurrent intraocular lymphoma. *British Journal of Ophthalmology* 1999;83:448-451.
4. Mietz H, Heimann K. Onset and recurrence of proliferative vitreoretinopathy in various vitreoretinal disease. *British Journal of Ophthalmology* 1995;79:874-877.
5. Pastor JC, la Rúa de ER, Martin F. Proliferative vitreoretinopathy: risk factors and pathobiology. *Progress in Retinal and Eye Research* 2002;21:127-144.
6. Hardwig PW, Pulido JS, Erie JC, et al. Intraocular Methotrexate in Ocular Diseases Other Than Primary Central Nervous System Lymphoma. *Am J Ophthalmol* 2006;142:883-885.
7. Hardwig PW, Pulido JS, Bakri SJ. The safety of intraocular methotrexate in silicone-filled eyes. *Retina* 2008;28:1082-1086.
8. Velez G, Yuan P, Sung C, et al. Pharmacokinetics and toxicity of intravitreal chemotherapy for primary intraocular lymphoma. *Arch Ophthalmol* 2001;119:1518-1524.
9. Cretien O, Spileers W, Stalmans P. Systemic resorption of 5-fluorouracil used in infusion fluid during vitrectomy. *Bull Soc Belge Ophtalmol* 2007;37-41.
10. Cheema RA, Peyman GA, Fang T, et al. Triamcinolone acetonide as an adjuvant in the surgical treatment of retinal detachment with proliferative vitreoretinopathy. *Ophthalmic Surg Lasers Imaging* 2007;38:365-370.
11. Ahmadi H, Feghhi M, Tabatabaei H, et al. Triamcinolone Acetonide in Silicone-Filled Eyes as Adjunctive Treatment for Proliferative Vitreoretinopathy. *Ophthalmology* 2008;115:1938-1943.
12. Yang CS, Khawly JA, Hainsworth DP, et al. An intravitreal sustained-release triamcinolone and 5-fluorouracil codrug in the treatment of experimental proliferative vitreoretinopathy. *Arch Ophthalmol* 1998;116:69-77.
13. Chen EP, Steinhorst UH, Samsa GP, et al. The effect of combined daunorubicin and triamcinolone acetonide treatment on a refined experimental model of proliferative vitreoretinopathy. *Investigative Ophthalmology & Visual Science* 1992;33:2160-2164.
14. Munir WM, Pulido JS, Sharma MC, Buerk BM. Intravitreal triamcinolone for treatment of complicated proliferative diabetic retinopathy and proliferative vitreoretinopathy. *Can J Ophthalmol* 2005;40:598-604.
15. Chandler DB, Rozakis G, de Juan E, Machemer R. The effect of triamcinolone acetonide on a refined experimental model of proliferative vitreoretinopathy. *AJOPHT* 1985;99:686-690.
16. Montesinos MC, Yap JS, Desai A, et al. Reversal of the antiinflammatory effects of methotrexate by the nonselective adenosine receptor antagonists theophylline and caffeine: evidence that the antiinflammatory effects of methotrexate are mediated via multiple adenosine receptors in rat adjuvant arthritis. *Arthritis Rheum* 2000;43:656-663.
17. Gerards AH, de Lathouder S, de Groot ER, et al. Inhibition of cytokine production by methotrexate. Studies in healthy volunteers and patients with rheumatoid arthritis. *Rheumatology (Oxford)* 2003;42:1189-1196.
18. Genestier L, Paillot R, Fournel S, et al. Immunosuppressive properties of methotrexate: apoptosis and clonal deletion of activated peripheral T cells. *J Clin Invest* 1998;102:322-328.
19. Seitz M, Zwicker M, Wider B. Enhanced in vitro induced production of interleukin 10 by peripheral blood mononuclear cells in rheumatoid arthritis is associated with clinical response to methotrexate treatment. *J Rheumatol* 2001;28:496-501.
20. Johnston A, Gudjonsson JE, Sigmundsdottir H, et al. The anti-inflammatory action of methotrexate is not mediated by lymphocyte apoptosis, but by the suppression of activation and adhesion molecules. *Clin Immunol* 2005;114:154-163.

OTHER EMBODIMENTS

[0068] It is to be understood that while the invention has been described in conjunction with the detailed description thereof, the foregoing description is intended to illustrate and not limit the scope of the invention, which is defined by the scope of the appended claims. Other aspects, advantages, and modifications are within the scope of the following claims.

Claims

1. A composition for use in treating or reducing the risk of proliferative vitreoretinopathy (PVR) or epiretinal membranes (ERM) in a subject, wherein the composition comprises methotrexate and the methotrexate is administered via a plurality of intravitreal injections over a period of at least one, two, three, or more months, given no more frequently than weekly.
2. The composition for the use of claim 1, comprising administering ten or more intravitreal injections of methotrexate.
3. The composition for the use of any one of claims 1 to 2, wherein each injection provides a dose of 400 mcg in 0.1 ml methotrexate.
4. The composition for the use of any one of claims 1 to 3, wherein the methotrexate is administered posterior to the limbus.
5. The composition for the use of any one of claims 1 to 4, wherein the subject is undergoing an ocular surgical procedure that increases the subject's risk of developing ERM or PVR, optionally wherein the ocular surgical procedure is a pars plana vitrectomy (PPV), Retinal Detachment (RD) surgery; ERM surgery; scleral buckle surgery; or a procedure in the other eye.
6. The composition for the use of claim 5, wherein the subject requires a PPV to treat a rhegmatogenous retinal detachment secondary to trauma; preexisting proliferative vitreoretinopathy; or for other indications associated with high risk condition for PVR development and optionally selected from the group consisting of a giant retinal tear, a retinal break larger than 3 disc areas, a long-standing retinal detachment, or a detachment associated with hemorrhage.
7. The composition for the use of claim 5, wherein:
 - a first injection is given at conclusion of the surgical procedure;
 - eight weekly injections are given until postoperative month two; and
 - a tenth injection is given at postoperative month three.
8. The composition for the use of any one of claims 1 to 6, comprising administering nine consecutive weekly injections, and a tenth injection three months after the first injection, and optionally administering additional injections after the tenth injection..
9. The composition for the use of claim 8, comprising administering one, two, three, four, five, six, seven, eight, or nine additional injections after the tenth injection.

Patentansprüche

1. Zusammensetzung zur Verwendung bei der Behandlung oder Verringerung des Risikos von proliferativer Vitreoretinopathie (PVR) oder epiretinalen Membranen (ERM) in einem Subjekt, wobei die Zusammensetzung Methotrexat umfasst und das Methotrexat durch eine Mehrzahl von intravitrealen Injektionen über einen Zeitraum von mindestens einem, zwei, drei oder mehr Monaten, nicht häufiger als wöchentlich gegeben, verabreicht wird.
2. Zusammensetzung zur Verwendung nach Anspruch 1, umfassend das Verabreichen von zehn oder mehr intravitrealen Injektionen von Methotrexat.
3. Zusammensetzung zur Verwendung nach einem der Ansprüche 1 bis 2, wobei jede Injektion eine Dosis von 400 mcg in 0,1 ml Methotrexat bereitstellt.
4. Zusammensetzung zur Verwendung nach einem der Ansprüche 1 bis 3, wobei das Methotrexat posterior zum Limbus verabreicht wird.
5. Zusammensetzung zur Verwendung nach einem der Ansprüche 1 bis 4, wobei das Subjekt einem augenchirurgischen Eingriff unterzogen wird, der das Risiko, dass das Subjekt ERM oder PVR entwickelt, erhöht, gegebenenfalls,

wobei der augenchirurgischen Eingriff eine Pars-plana-Vitrektomie (PPV), Netzhautablösungs-(RD) Operation; ERM-Operation; Skleraplomben-Operation; oder ein Eingriff in dem anderen Auge ist.

6. Zusammensetzung zur Verwendung nach Anspruch 5, wobei das Subjekt eine PPV zur Behandlung einer rhegmatagenen Netzhautablösung sekundär zu Trauma; einer bereits existierenden proliferativen Vitreoretinopathie; oder bei anderen Anzeigen erfordert, die mit hohem Risiko einer PVR-Entstehung verbunden und gegebenenfalls ausgewählt sind aus der Gruppe bestehend aus einem Riesenriss der Netzhaut, einem Netzhautriss größer als 3 Papillenflächen, einer seit langem bestehenden Netzhautablösung oder einer mit Blutung assoziierten Ablösung.

7. Zusammensetzung zur Verwendung nach Anspruch 5, wobei:

eine erste Injektion am Abschluss des operativen Eingriffs gegeben wird;
acht wöchentliche Injektionen bis zum postoperativen Monat zwei gegeben werden; und
eine zehnte Injektion im postoperativen Monat drei gegeben wird.

8. Zusammensetzung zur Verwendung nach einem der Ansprüche 1 bis 6, umfassend das Verabreichen von neun aufeinanderfolgenden wöchentlichen Injektionen und einer zehnten Injektion drei Monate nach der ersten Injektion, und gegebenenfalls das Verabreichen zusätzlicher Injektionen nach der zehnten Injektion.

9. Zusammensetzung zur Verwendung nach Anspruch 8, umfassend das Verabreichen von einer, zwei, drei, vier, fünf, sechs, sieben, acht oder neun zusätzlichen Injektionen nach der zehnten Injektion.

Revendications

1. Composition pour une utilisation dans le traitement ou la réduction du risque de vitréorétinopathie proliférante (PVR) ou de membranes épirétiniennes (ERM) chez un sujet, dans laquelle la composition comprend un méthotrexate et le méthotrexate est administré via une pluralité d'injections intravitréennes sur une période d'au moins un, deux, trois mois ou plus, faites pas plus souvent qu'une fois par semaine.

2. Composition pour l'utilisation selon la revendication 1, comprenant l'administration de dix injections intravitréennes de méthotrexate ou plus.

3. Composition pour l'utilisation selon l'une quelconque des revendications 1 à 2, dans laquelle chaque injection fournit une dose de 400 mcg dans 0,1 ml de méthotrexate.

4. Composition pour l'utilisation selon l'une quelconque des revendications 1 à 3, dans laquelle le méthotrexate est administré à l'arrière du limbe.

5. Composition pour l'utilisation selon l'une quelconque des revendications 1 à 4, dans laquelle le sujet subit une intervention chirurgicale oculaire qui augmente le risque du sujet de développer ERM ou PVR, en option dans laquelle l'intervention chirurgicale oculaire est une vitrectomie par la pars plana (PPV), une intervention chirurgicale du décollement de la rétine (RD); une intervention chirurgicale ERM; une intervention chirurgicale du cerclage scléral; ou une intervention chirurgicale dans l'autre œil.

6. Composition pour l'utilisation selon la revendication 5, dans laquelle le sujet nécessite un PPV pour traiter un décollement de la rétine rhégmatagène consécutif à un traumatisme; une vitréorétinopathie proliférante pré-existante; ou pour d'autres indications associées à une condition à haut risque d'un développement du PVR et en option, sélectionnées dans le groupe constitué d'une déchirure rétinienne énorme, une rupture rétinienne plus grande que 3 surfaces de disque, un décollement de la rétine de longue date ou un décollement associé à une hémorragie.

7. Composition pour l'utilisation selon la revendication 5, dans laquelle :

une première injection est faite à la fin de l'intervention chirurgicale;
huit injections hebdomadaires sont faites jusqu'à deux mois après l'opération; et
une dixième injection est faite trois mois après l'opération.

EP 3 174 540 B9

8. Composition pour l'utilisation selon l'une quelconque des revendications 1 à 6, comprenant l'administration de neuf injections hebdomadaires consécutives, et une dixième injection trois mois après la première injection et en option, administrer des injections additionnelles après la dixième injection.

5 9. Composition pour l'utilisation selon la revendication 8, comprenant l'administration d'une, deux, trois, quatre, cinq, six, sept, huit ou neuf injections additionnelles après la dixième injection.

10

15

20

25

30

35

40

45

50

55

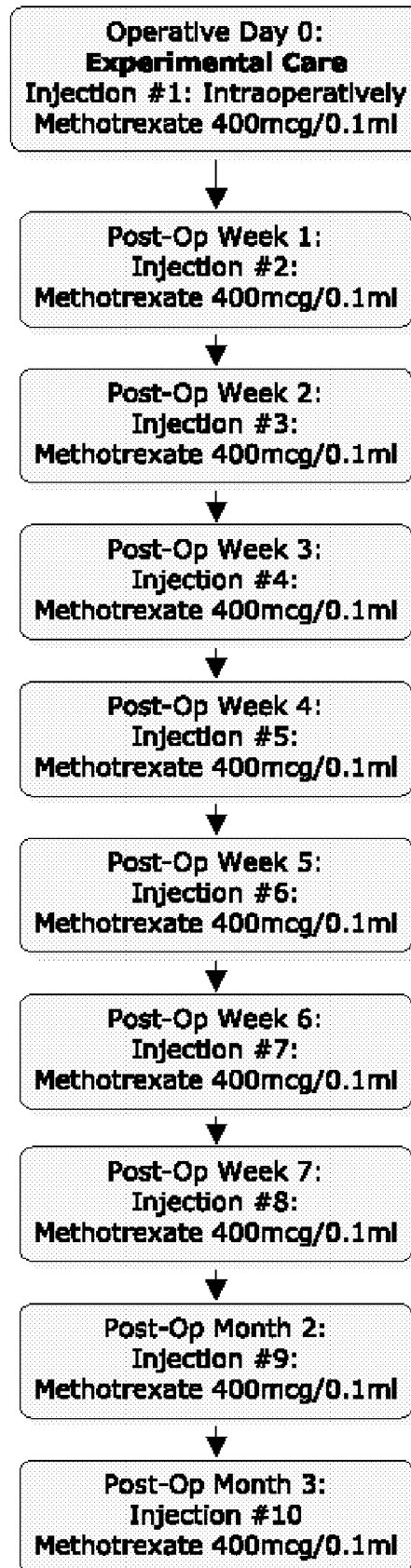


FIG. 1

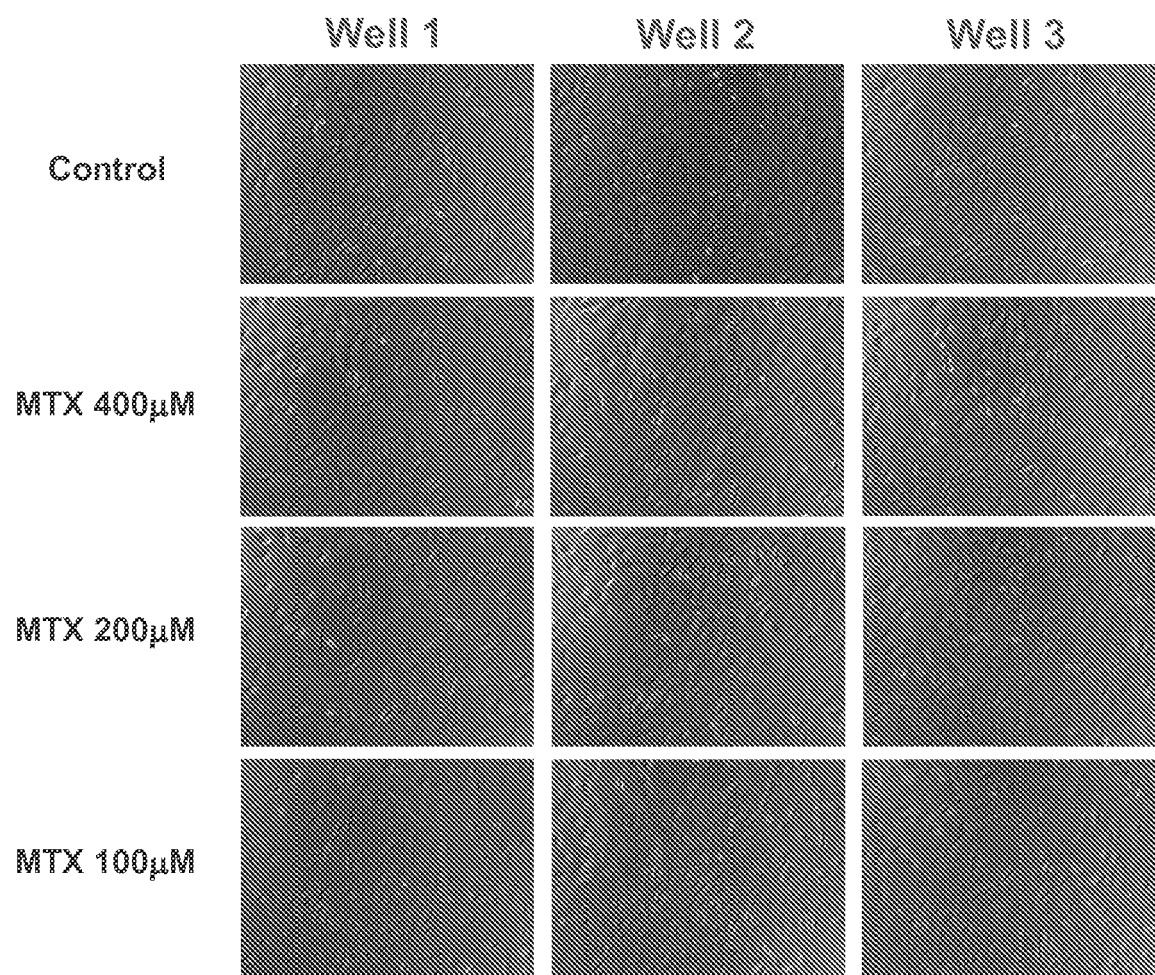


FIG. 2A

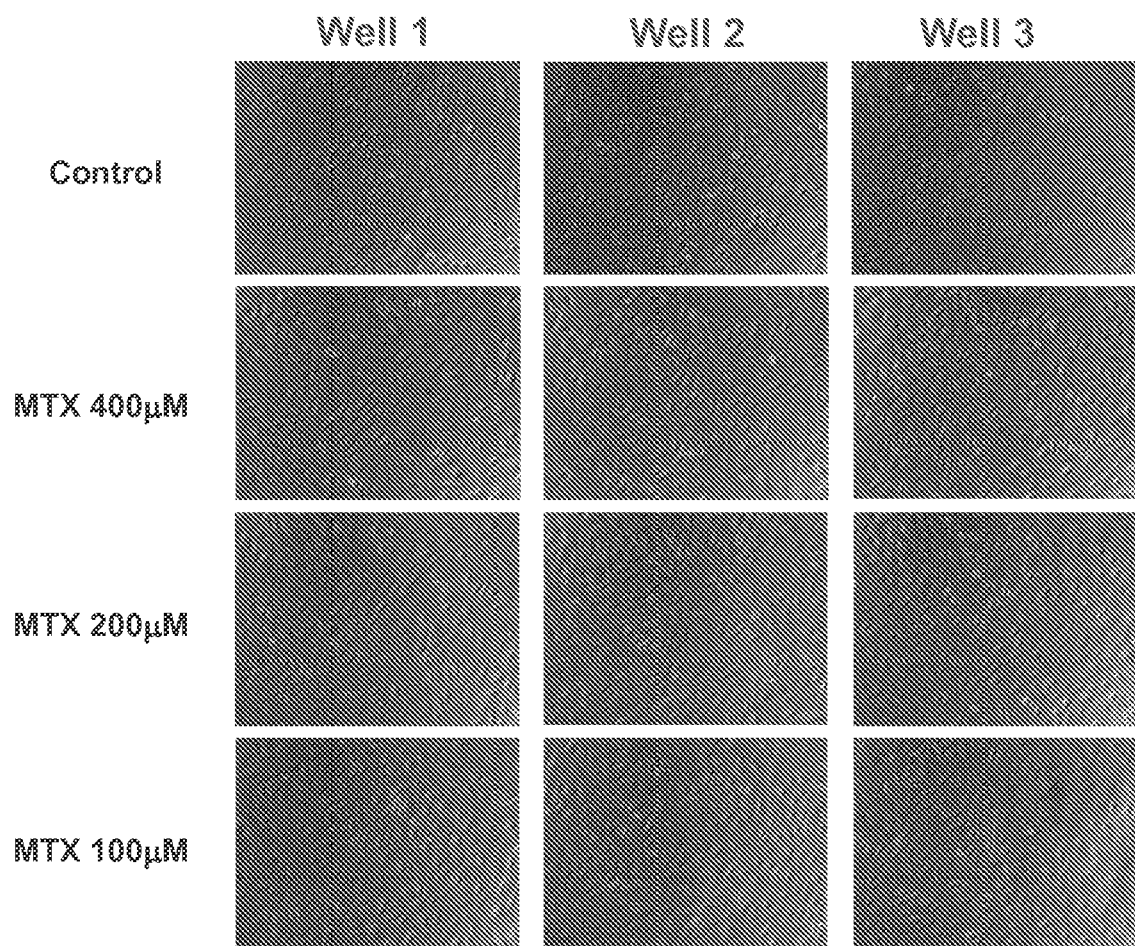


FIG. 2B

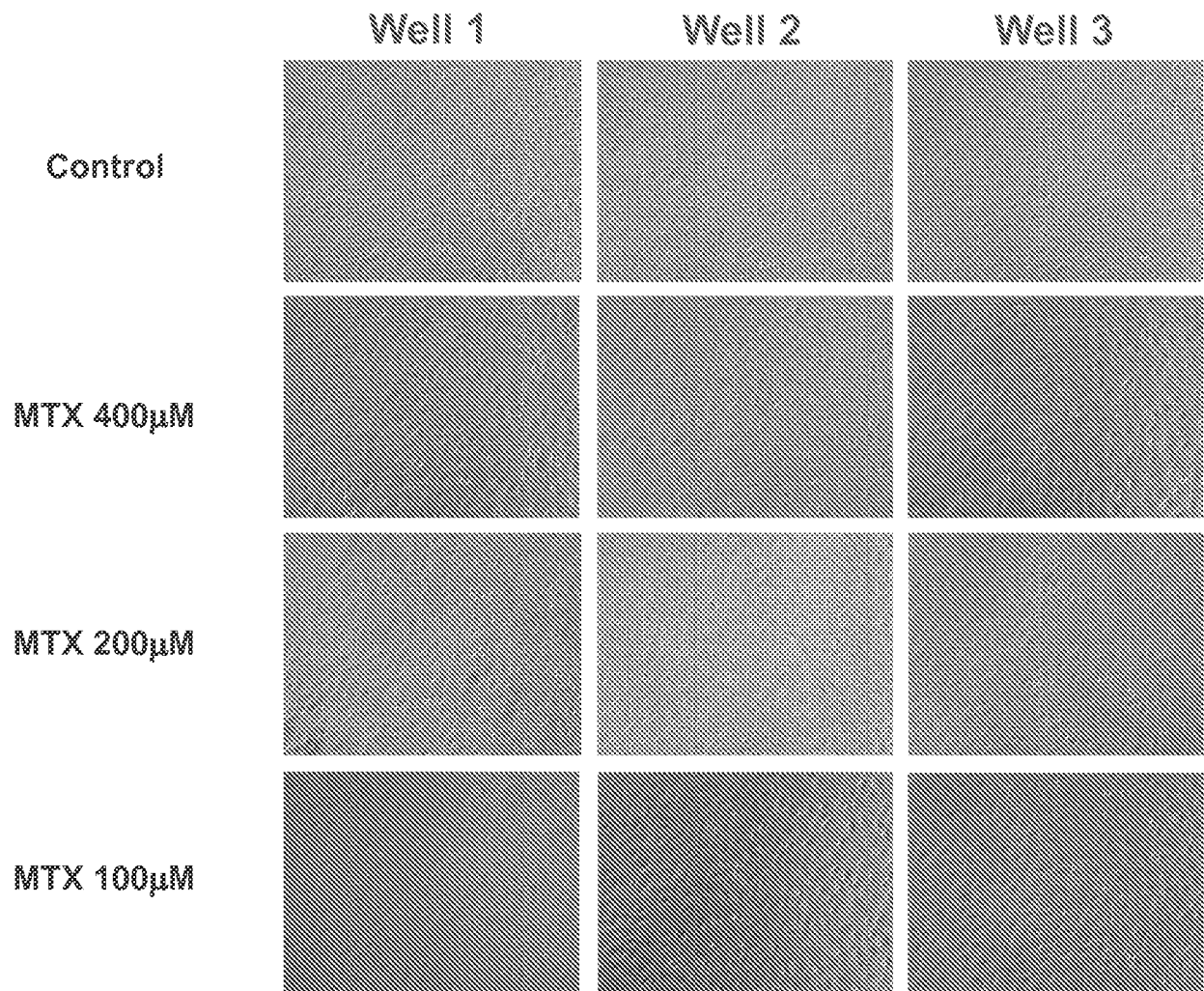


FIG. 2C

REFERENCES CITED IN THE DESCRIPTION

This list of references cited by the applicant is for the reader's convenience only. It does not form part of the European patent document. Even though great care has been taken in compiling the references, errors or omissions cannot be excluded and the EPO disclaims all liability in this regard.

Patent documents cited in the description

- US 62030778 [0001]
- WO 2011143484 A [0036]

Non-patent literature cited in the description

- **SUNALP M et al.** Effects of cytotoxic drugs on proliferative vitreoretinopathy in the rabbit cell injection model. *CURRENT EYE RESEARCH*, 31 March 1984, vol. 3 (4), 619-623 [0007]
- **HISCOTT et al.** *Br J Ophthalmol.*, 1984, vol. 68 (10), 708-15 [0029]
- **HISCOTT et al.** *Eye*, 2002, vol. 16, 393-403 [0029]
- **ASATO et al.** *PLoS One*, 2013, vol. 8 (1), e54191 [0029]
- **BONETTI et al.** *Cancer Chemother Pharmacol*, 1994, vol. 33, 303-306 [0036]
- **CHATELUT et al.** *J Pharm Sci.*, March 1994, vol. 83 (3), 429-32 [0036]
- **VIJAYARAGAVAN et al.** *Int J Pharm Res*, 2011, vol. 3 (1), 39-44 [0036]
- **TAHERI et al.** *J Nanomaterials*, 2011 [0036]
- **PALAKURTHI et al.** *Current Eye Research*, 2010, vol. 35 (12), 1105-1115 [0037]
- **LEE et al.** *Pharm Res.*, 2010, vol. 27 (10), 2043-53 [0037]
- **HAGHJOU et al.** *J Ophthalmic Vis Res.*, 2011, vol. 6 (4), 317-329 [0037]
- **KIM et al.** *Invest. Ophthalmol. Vis. Sci.*, 2004, vol. 45 (8), 2722-2731 [0037]
- **VELEZ ; WHITCUP.** *Br J Ophthalmol*, 1999, vol. 83, 1225-1229 [0037]
- **RYAN.** *Retina*. Elsevier, 2013 [0044]
- Retina Society Terminology Committee. The classification of retinal detachment with proliferative vitreoretinopathy. *Ophthalmology*, 1983, vol. 90, 121-5 [0044]
- **MACHEMER R ; AABERG TM ; FREEMAN HM et al.** *Am J Ophthalmol*, 1991, vol. 112, 159-65 [0044]
- **LEAN J ; IRVINE A ; STERN W et al.** Classification of proliferative vitreoretinopathy used in the silicone study. The Silicone study group. *Ophthalmology*, 1989, vol. 96, 765-771 [0044]
- **HARDWIG et al.** *Retina*, 2008, vol. 28, 1082-1086 [0063]
- **HARDWIG et al.** *Am J Ophthalmol*, 2006, vol. 142, 883-885 [0063]
- **FRENKEL S ; HENDLER K ; SIEGAL T et al.** Intravitreal methotrexate for treating vitreoretinal lymphoma: 10 years of experience. *British Journal of Ophthalmology*, 2008, vol. 92, 383-388 [0067]
- **FISHBURNE BC ; WILSON DJ ; ROSENBAUM JT ; NEUWELT EA.** Intravitreal methotrexate as an adjunctive treatment of intraocular lymphoma. *Arch Ophthalmol*, 1997, vol. 115, 1152-1156 [0067]
- **DE SMET MD ; VANCs VS ; KOHLER D et al.** Intravitreal chemotherapy for the treatment of recurrent intraocular lymphoma. *British Journal of Ophthalmology*, 1999, vol. 83, 448-451 [0067]
- **MIETZ H ; HEIMANN K.** Onset and recurrence of proliferative vitreoretinopathy in various vitreoretinal disease. *British Journal of Ophthalmology*, 1995, vol. 79, 874-877 [0067]
- **PASTOR JC ; LA RÚA DE ER ; MARTIN F.** Proliferative vitreoretinopathy: risk factors and pathobiology. *Progress in Retinal and Eye Research*, 2002, vol. 21, 127-144 [0067]
- **HARDWIG PW ; PULIDO JS ; ERIE JC et al.** Intravitreal Methotrexate in Ocular Diseases Other Than Primary Central Nervous System Lymphoma. *Am J Ophthalmol*, 2006, vol. 142, 883-885 [0067]
- **HARDWIG PW ; PULIDO JS ; BAKRI SJ.** The safety of intravitreal methotrexate in silicone-filled eyes. *Retina*, 2008, vol. 28, 1082-1086 [0067]
- **VELEZ G ; YUAN P ; SUNG C et al.** Pharmacokinetics and toxicity of intravitreal chemotherapy for primary intraocular lymphoma. *Arch Ophthalmol*, 2001, vol. 119, 1518-1524 [0067]
- **CRETEN O ; SPILEERS W ; STALMANS P.** Systemic resorption of 5-fluorouracil used in infusion fluid during vitrectomy. *Bull Soc Belge Ophthalmol*, 2007, 37-41 [0067]
- **CHEEMA RA ; PEYMAN GA ; FANG T et al.** Triamcinolone acetonide as an adjuvant in the surgical treatment of retinal detachment with proliferative vitreoretinopathy. *Ophthalmic Surg Lasers Imaging*, 2007, vol. 38, 365-370 [0067]

- **AHMADIEH H ; FEGHHI M ; TABATABAEI H et al.** Triamcinolone Acetonide in Silicone-Filled Eyes as Adjunctive Treatment for Proliferative Vitreoretinopathy. *Ophthalmology*, 2008, vol. 115, 1938-1943 [0067]
- **YANG CS ; KHAWLY JA ; HAINSWORTH DP et al.** An intravitreal sustained-release triamcinolone and 5-fluorouracil codrug in the treatment of experimental proliferative vitreoretinopathy. *Arch Ophthalmol*, 1998, vol. 116, 69-77 [0067]
- **CHEN EP ; STEINHORST UH ; SAMSA GP et al.** The effect of combined daunorubicin and triamcinolone acetonide treatment on a refined experimental model of proliferative vitreoretinopathy. *Investigative Ophthalmology & Visual Science*, 1992, vol. 33, 2160-2164 [0067]
- **MUNIR WM ; PULIDO JS ; SHARMA MC ; BUERK BM.** Intravitreal triamcinolone for treatment of complicated proliferative diabetic retinopathy and proliferative vitreoretinopathy. *Can J Ophthalmol*, 2005, vol. 40, 598-604 [0067]
- **CHANDLER DB ; ROZAKIS G ; DE JUAN E ; MACHEMER R.** The effect of triamcinolone acetonide on a refined experimental model of proliferative vitreoretinopathy. *AJOPHT*, 1985, vol. 99, 686-690 [0067]
- **MONTESINOS MC ; YAP JS ; DESAI A et al.** Reversal of the antiinflammatory effects of methotrexate by the nonselective adenosine receptor antagonists theophylline and caffeine: evidence that the antiinflammatory effects of methotrexate are mediated via multiple adenosine receptors in rat adjuvant arthritis. *Arthritis Rheum*, 2000, vol. 43, 656-663 [0067]
- **GERARDS AH ; DE LATHOUDER S ; DE GROOT ER et al.** Inhibition of cytokine production by methotrexate. Studies in healthy volunteers and patients with rheumatoid arthritis. *Rheumatology (Oxford)*, 2003, vol. 42, 1189-1196 [0067]
- **GENESTIER L ; PAILLOT R ; FOURNEL S et al.** Immunosuppressive properties of methotrexate: apoptosis and clonal deletion of activated peripheral T cells. *J Clin Invest*, 1998, vol. 102, 322-328 [0067]
- **SEITZ M ; ZWICKER M ; WIDER B.** Enhanced in vitro induced production of interleukin 10 by peripheral blood mononuclear cells in rheumatoid arthritis is associated with clinical response to methotrexate treatment. *J Rheumatol*, 2001, vol. 28, 496-501 [0067]
- **JOHNSTON A ; GUDJONSSON JE ; SIGMUNDSDOTTIR H et al.** The anti-inflammatory action of methotrexate is not mediated by lymphocyte apoptosis, but by the suppression of activation and adhesion molecules. *Clin Immunol*, 2005, vol. 114, 154-163 [0067]